

Third-generation neuroimaging: Translating the research evidence into clinical utility

Stefan Borgwardt

Department of Psychiatry, University of Basel

Institute of Psychiatry, King's College London

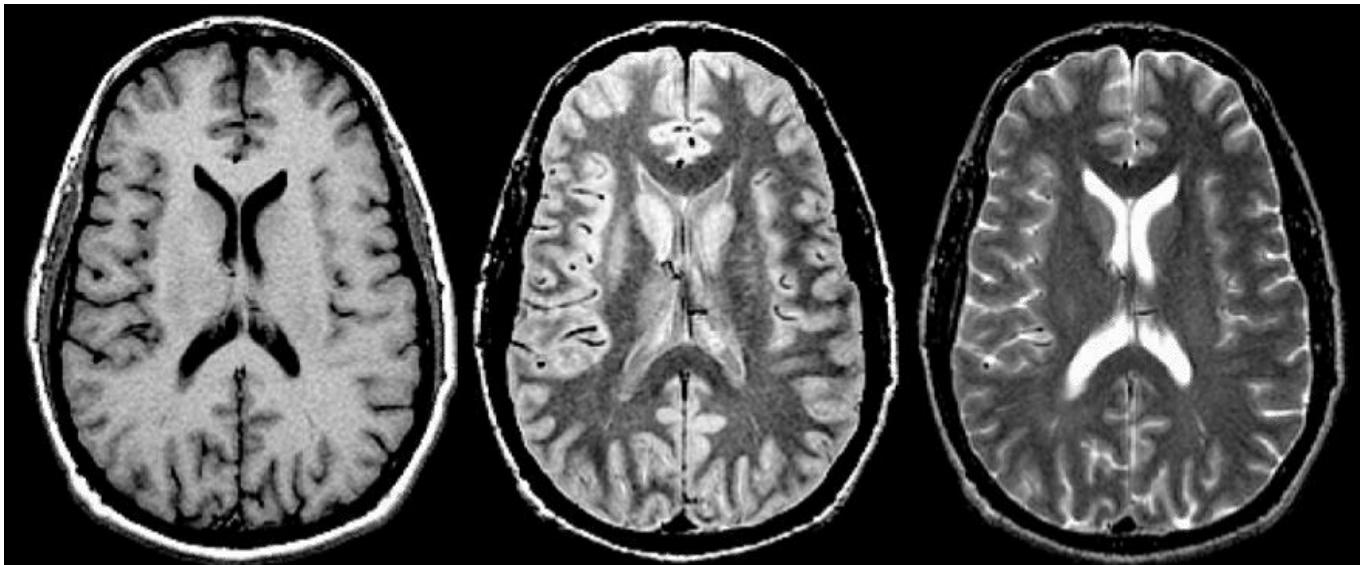
Clinical Neuroimaging

› Tissue-specific parameters:

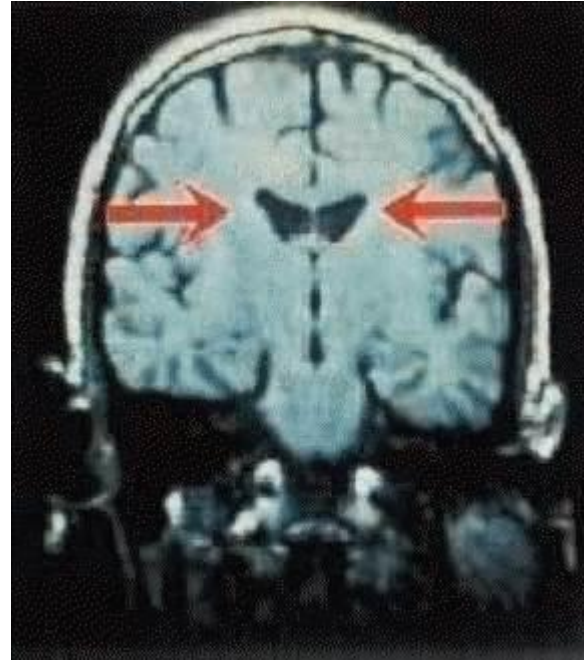
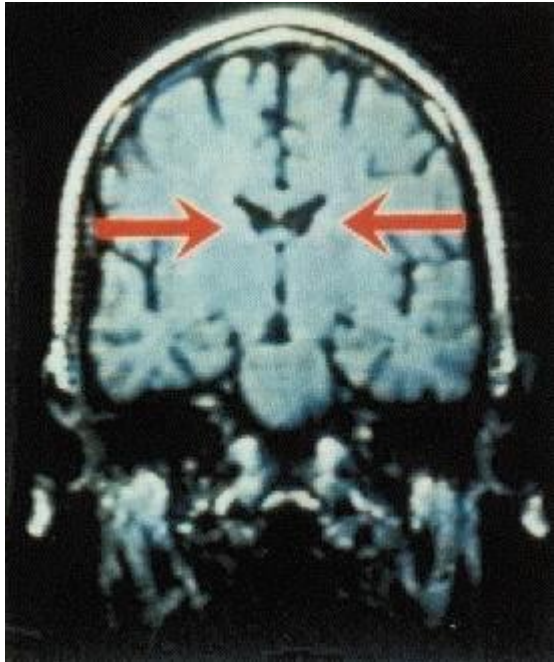
- T₁
- Proton density (PD)
- T₂/T₂*

› Scanning – parameters:

- Repetition Time (TR)
- Pulse (TE)



Ventricular enlargement in schizophrenia

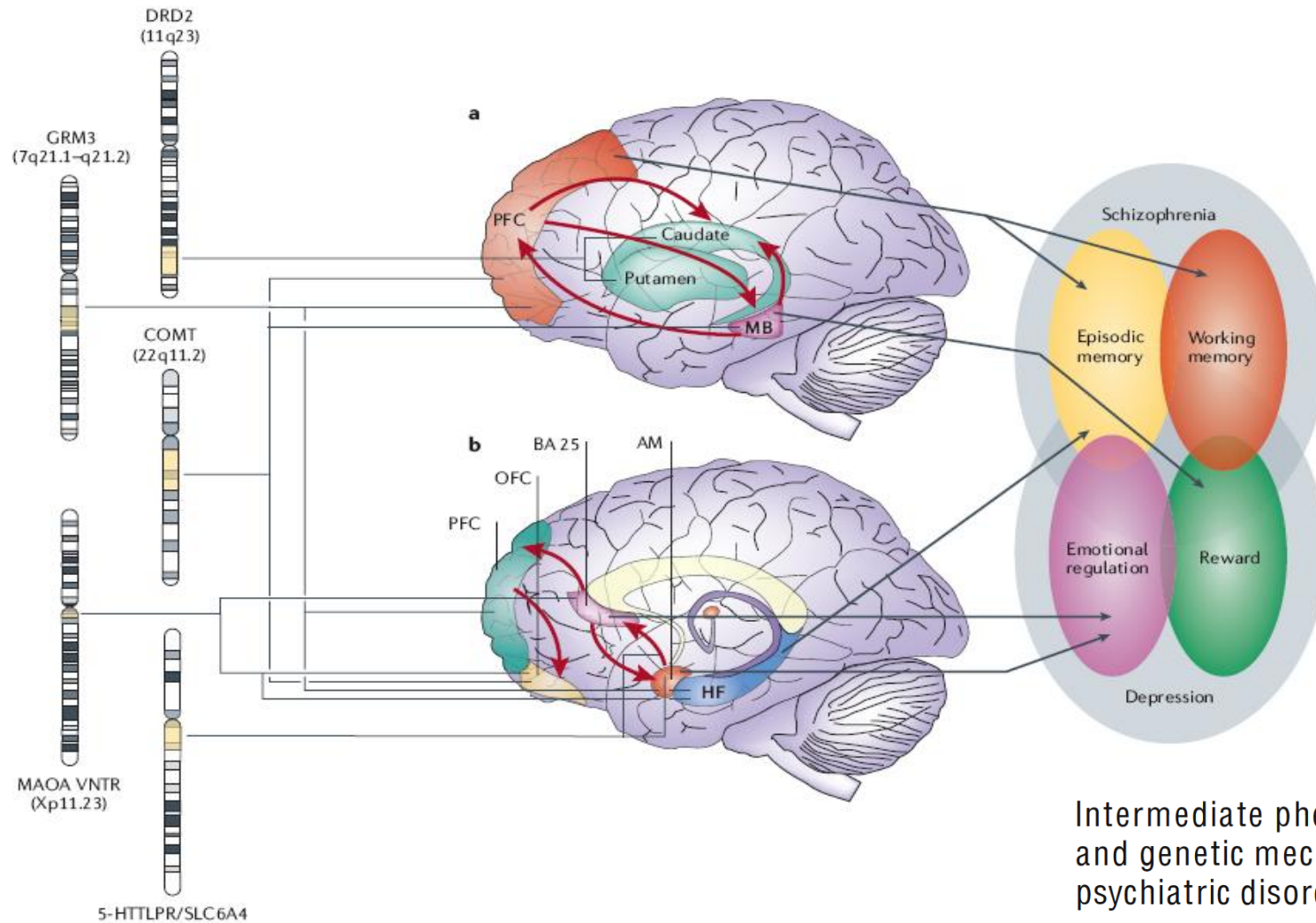


From clinical towards second-generation neuroimaging

- › Simple structural brain alterations associated with the neurobiology of the illness (computerised tomography (CT) to investigate brain size abnormalities etc)
- › More sophisticated techniques: whole-brain automated methods (voxel-based morphometry), white-matter methods (diffusion tensor imaging, tractography)
- › Functional methods (functional magnetic resonance imaging, fMRI)
- › Advanced neurochemical and pharmacological imaging (PET techniques addressing receptor bindings and pre-/post-synaptic functions, magnetic resonance spectroscopy, MRS)
- › Multimodal approaches
- › Multi-center analyses and meta-analytical imaging methods

Meyer-Lindenberg A and Weinberger DR *Nat Rev Neurosci.* 2006 7:818--27.

Genotype – Endophenotype - Phenotype



Intermediate phenotypes and genetic mechanisms of psychiatric disorders

Andreas Meyer-Lindenberg and Daniel R. Weinberger

Nat Rev Neurosci: 2006 Oct;7(10):818-27.

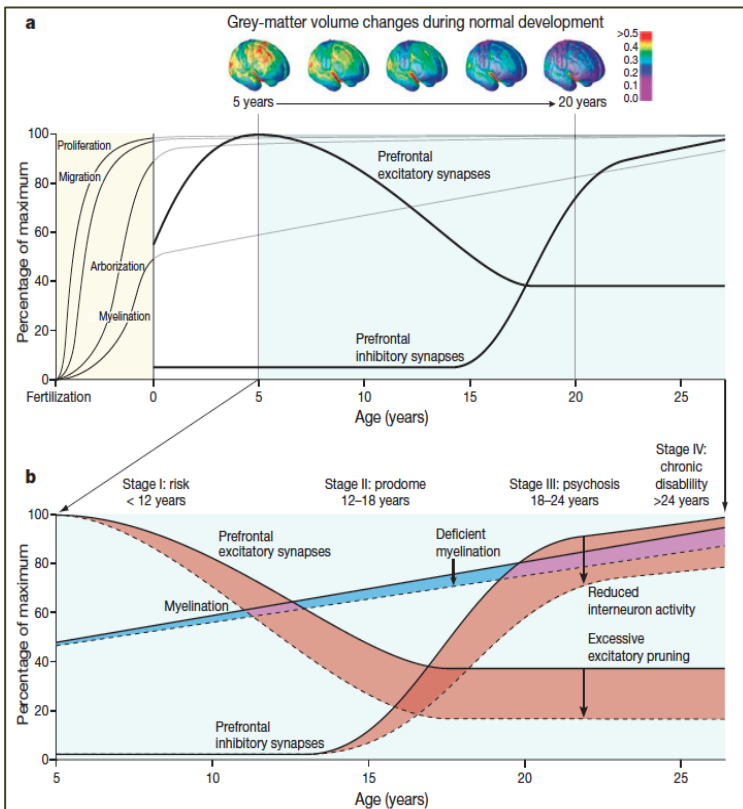
Current state

- No consistent or reliable anatomical or functional alterations have been unequivocally associated with psychosis or schizophrenia
- No clinical applications have been developed in psychiatric neuroimaging

Staging model of schizophrenia

	Stage I	Stage II	Stage III	Stage IV
Features	Genetic vulnerability Environmental exposure	Cognitive, behavioural and social deficits Help-seeking	Abnormal thought and behaviour Relapsing–remitting course	Loss of function Medical complications Incarceration
Diagnosis	Genetic sequence Family history	SIPS Cognitive assessment Imaging	Clinical interview Loss of insight	Clinical interview Loss of function
Disability	None/mild cognitive deficit	Change in school and social function	Acute loss of function Acute family distress	Chronic disability Unemployment Homelessness
Intervention	Unknown	Cognitive training? Polyunsaturated fatty acids? Family support?	Medication Psychosocial interventions	Medication Psychosocial interventions Rehabilitation services

Stage I, pre-symptomatic risk; stage II, pre-psychotic prodrome; stage III, acute psychosis; stage IV, chronic illness.



Back to the Future

Predicting and Reshaping the Course of Psychotic Disorder

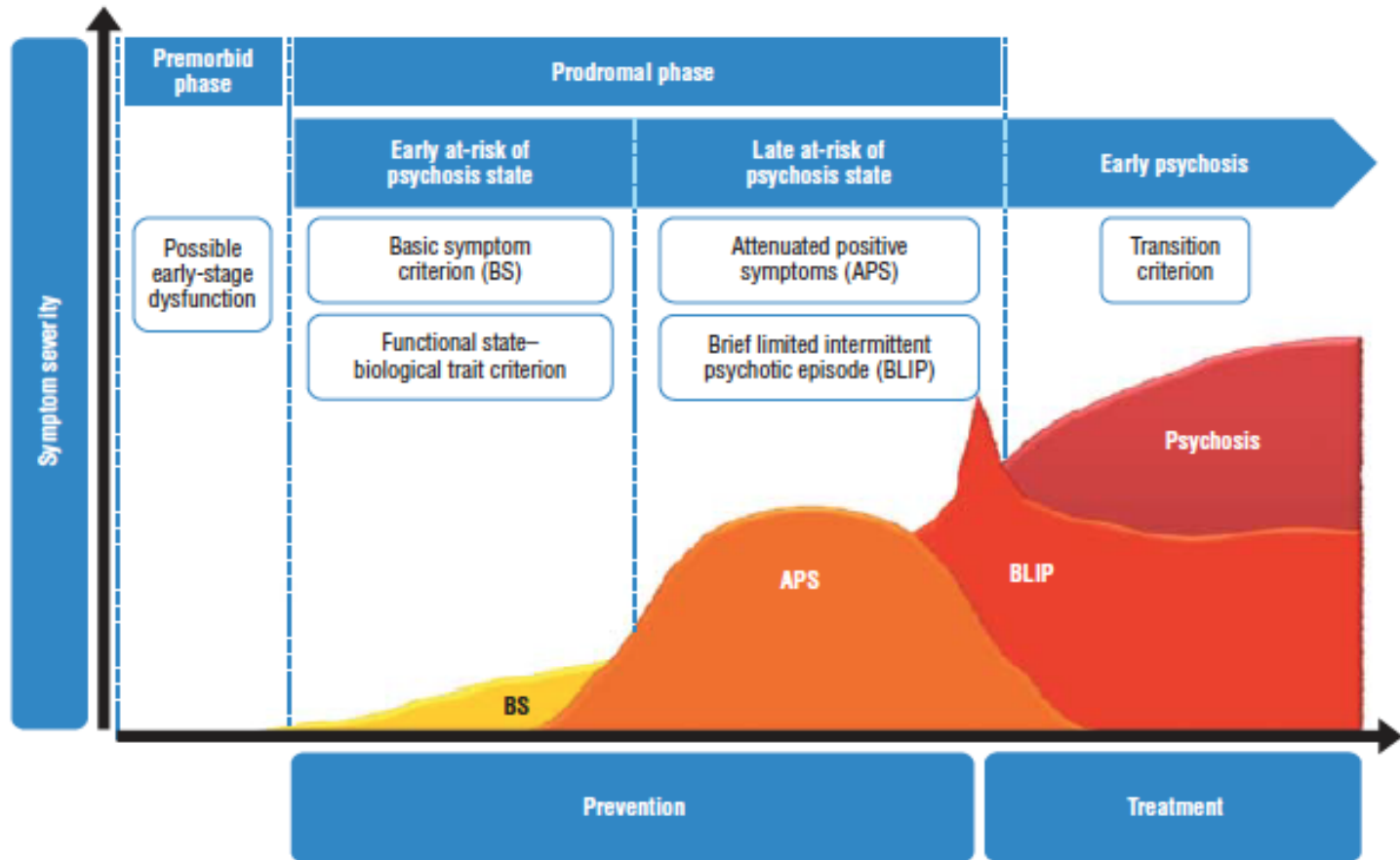
ARCH GEN PSYCHIATRY/VOL 65 (NO. 1), JAN 2008

doi:10.1038/nature09552

Rethinking schizophrenia

Thomas R. Insel¹

Model of psychosis onset from clinical high-risk state



The Psychosis High-Risk State

A Comprehensive State-of-the-Art Review

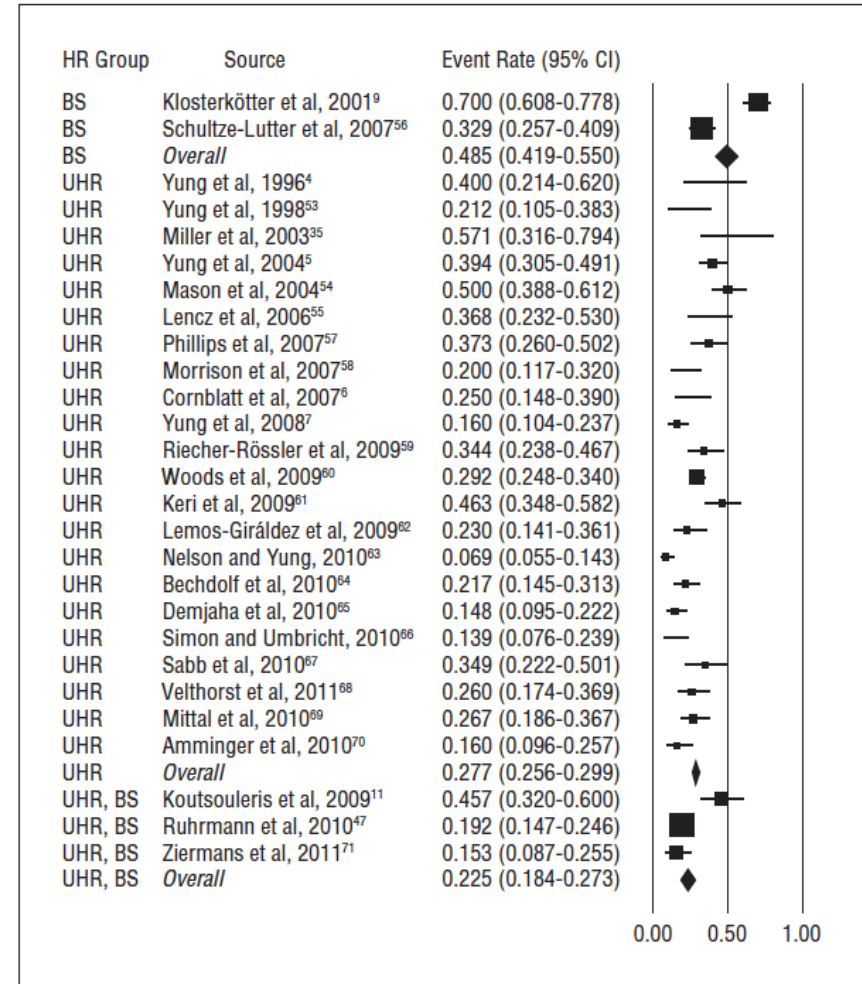
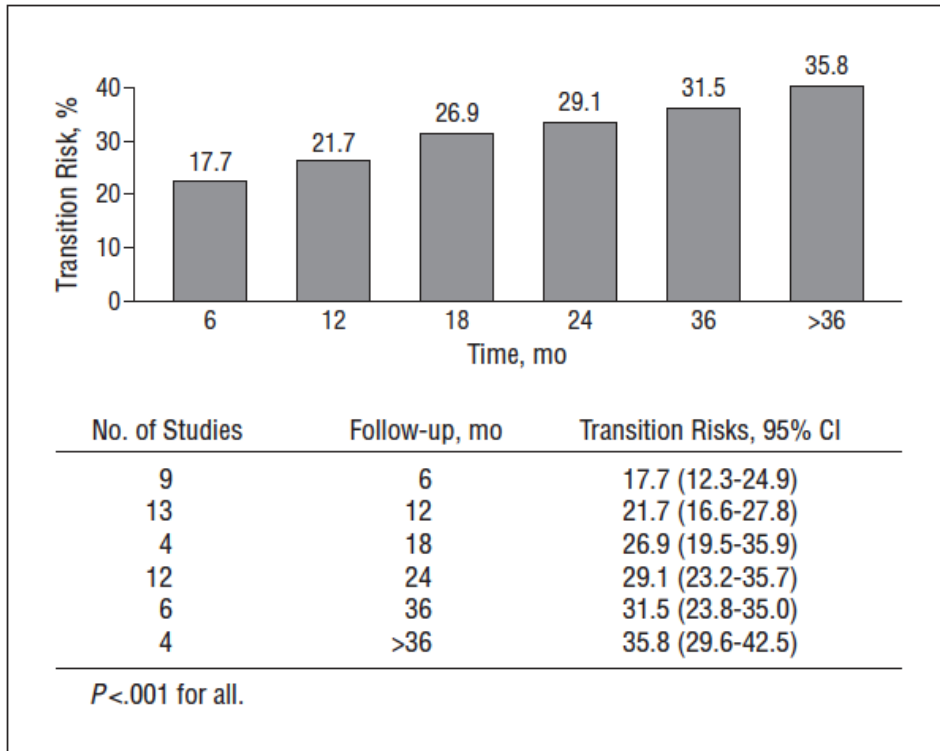
Paolo Fusar-Poli, MD, PhD; Stefan Borgwardt, MD, PhD; Andreas Bechdolf, MD; Jean Addington, PhD; Anita Riecher-Rössler, MD, PhD; Frauke Schultze-Lutter, PhD; Matcheri Keshavan, MD; Stephen Wood, MD, PhD; Stephan Ruhrmann, MD, PhD; Larry J. Seidman, MD, PhD; Lucia Valmaggia, MSc, PhD; Tyrone Cannon, PhD; Eva Velthorst, MSc, PhD; Lieuwe De Haan, MD, PhD; Barbara Cornblatt, MBA, PhD; Ilaria Bonoldi, MD; Max Birchwood, DSc; Thomas McGlashan, MD; William Carpenter, MD; Patrick McGorry, MD; Joachim Klosterkötter, MD, PhD; Philip McGuire, MD, PhD; Alison Yung, MD

JAMA Psychiatry. 2013;70(1):107-120.

Predicting Psychosis

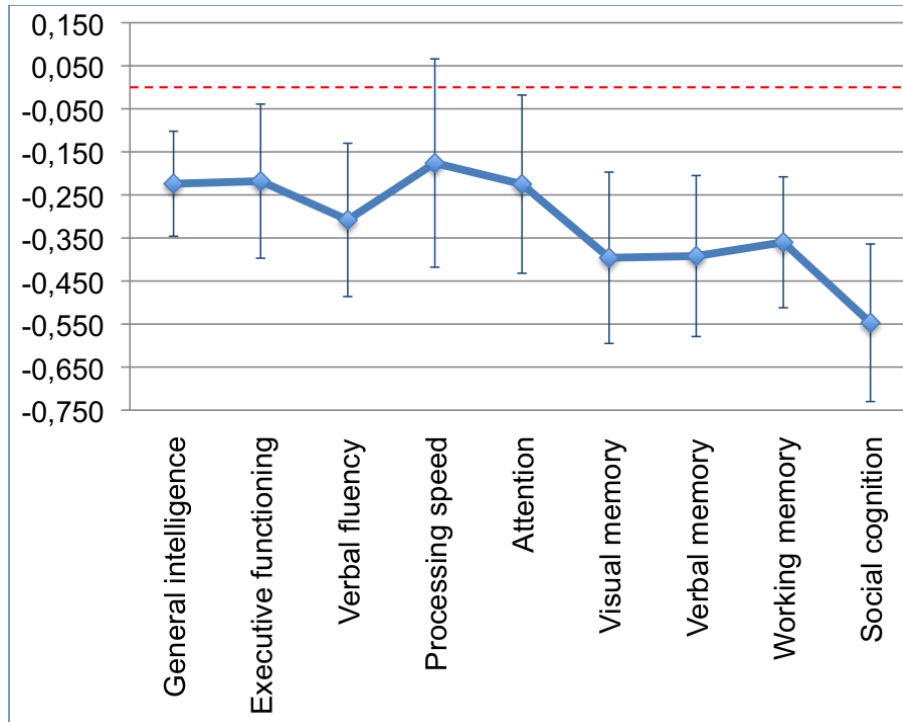
Meta-analysis of Transition Outcomes in Individuals at High Clinical Risk

Paolo Fusar-Poli, MD, PhD; Ilaria Bonoldi, MD; Alison R. Yung, PhD; Stefan Borgwardt, PhD;
 Matthew J. Kempton, PhD; Lucia Valmaggia, PhD; Francesco Barale, PhD;
 Edgardo Caverzasi, PhD; Philip McGuire, PhD

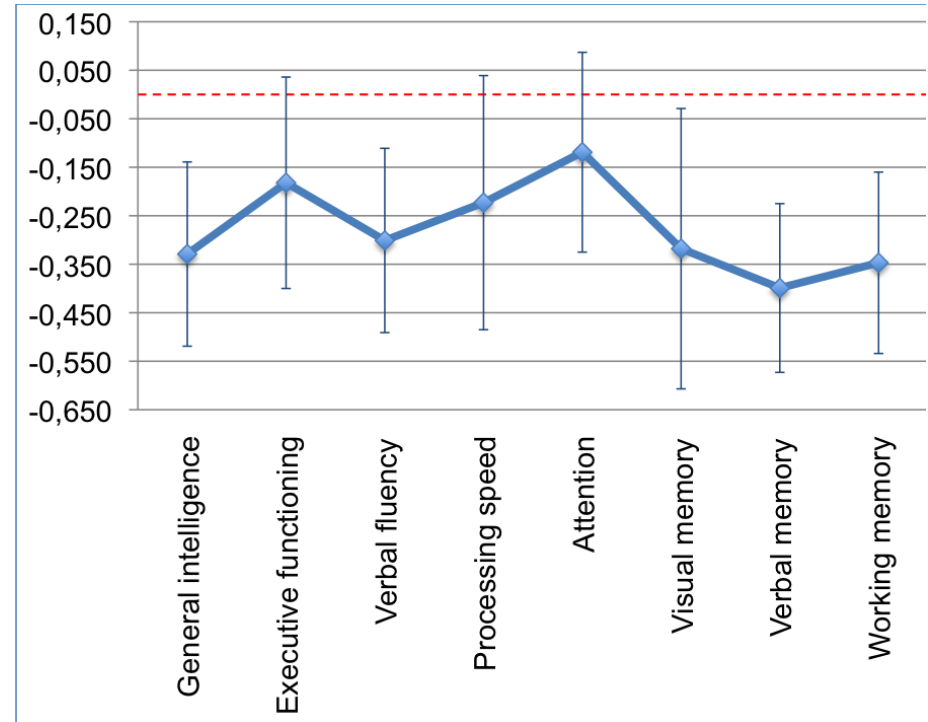


Meta-Analysis of cognitive functioning in prodromal psychosis

High-risk (HR) vs. controls



HR with transition vs. without transition

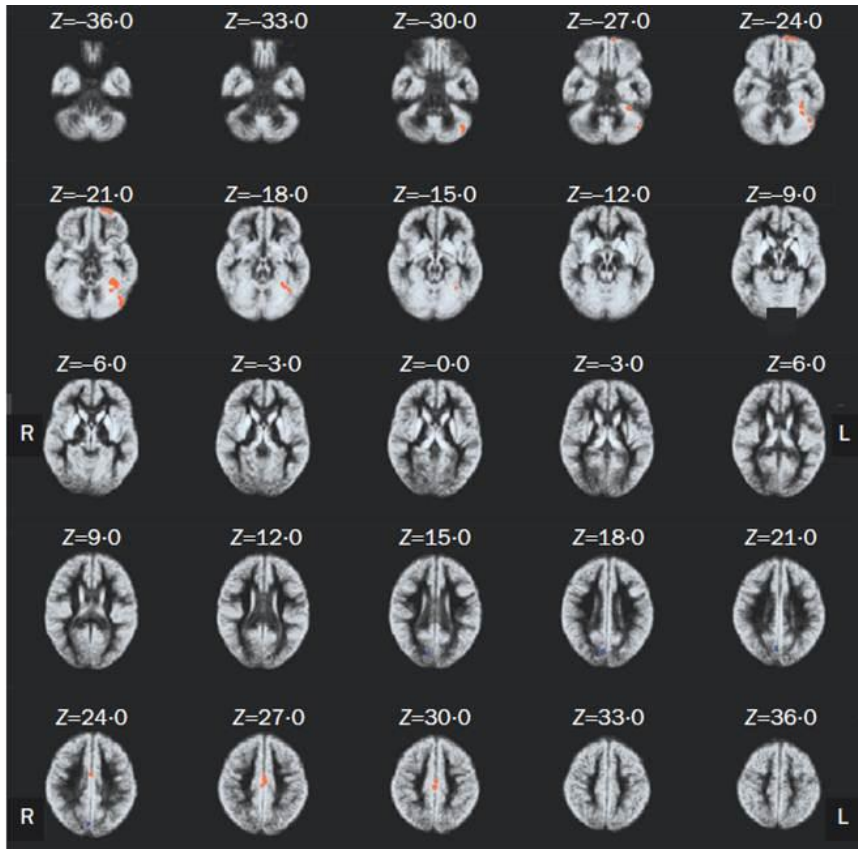


Cognitive Functioning in Prodromal Psychosis

A Meta-analysis

Paolo Fusar-Poli, MD, PhD; Giacomo Deste, MD; Renata Smieskova, PhD; Stefano Barlati, MD; Alison R. Yung, MD; Oliver Howes, BM, BCh, MA, MRCPsych, PhD, DM; Rolf-Dieter Stieglitz, PhD; Antonio Vita, MD, PhD; Philip McGuire, BSc, MB, ChB, MD, PhD, FRCPsych; Stefan Borgwardt, MD, PhD

Progressive gray matter volume reductions in ARMS with later transition to psychosis (VBM)

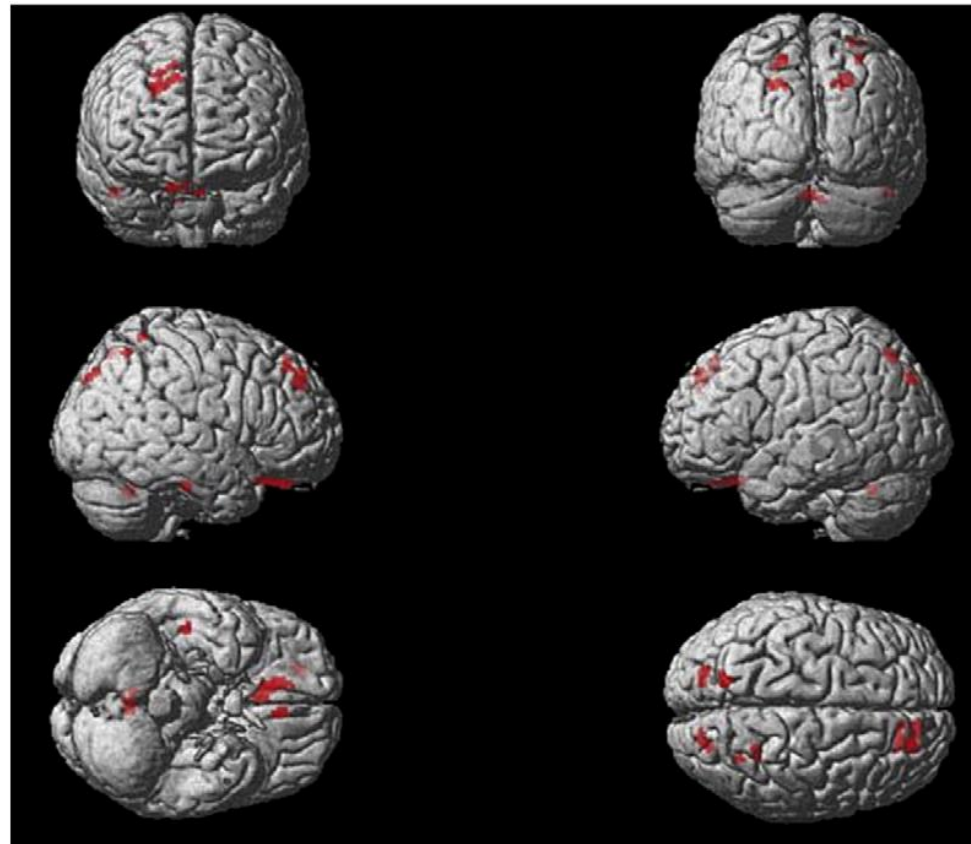


ARMS-T: L PHP, OF, Cerebellum;
Bilateral: CC

@Neuroanatomical abnormalities before and after onset of psychosis: a cross-sectional and longitudinal MRI comparison

Christos Pantelis, Dennis Velakoulis, Patrick D McGorry, Stephen J Wood, John Suckling, Lisa J Phillips, Alison R Yung, Edward T Bullmore, Warrick Brewer, Bridget Soulsby, Patricia Desmond, Philip K McGuire

Lancet 2003; **361**: 281–88. Published online Dec 10, 2002



ARMS-T: OF, SFG, ITG, SPC, MPC, Cerebellum

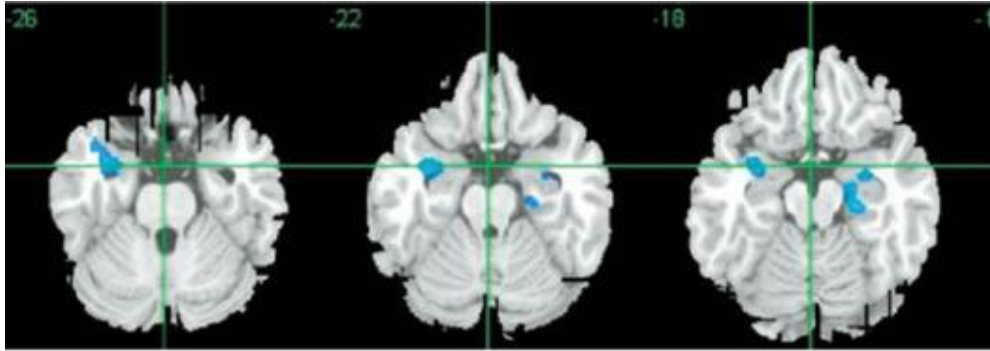
Reductions in frontal, temporal and parietal volume associated with the onset of psychosis

Stefan J. Borgwardt^{a,b,c,*}, Philip K. McGuire^c, Jacqueline Aston^a, Ute Gschwandtner^a, Marlon O. Pflüger^a, Rolf-Dieter Stieglitz^a, Ernst-Wilhelm Radue^b, Anita Riecher-Rössler^a

Schizophrenia Research 106 (2008) 108–114

Gray matter abnormalities before the onset of psychosis

ARMS vs. Controls: GM reduction mediotemporal and prefrontal



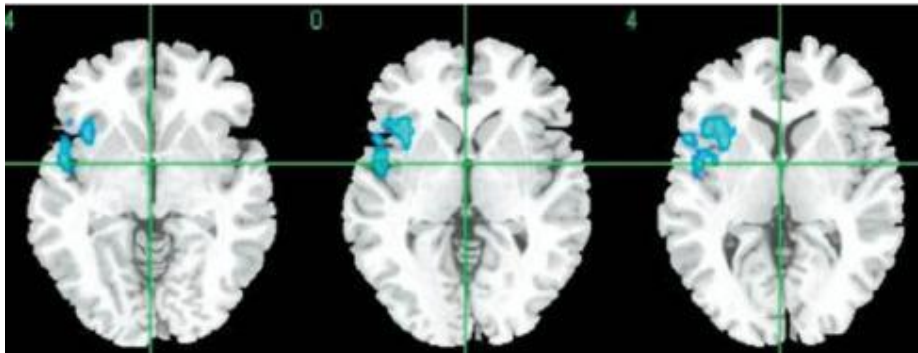
Structural brain abnormalities in individuals with an at-risk mental state who later develop psychosis

STEFAN J. BORGWARDT, PHILIP K. MCGUIRE, JACQUELINE ASTON, GREGOR BERGER, PAOLA DAZZAN, UTE GSCHWANDTNER, MARLON PFLÜGER, MARCUS D'SOUZA, ERNST-WILHELM RADUE and ANITA RIECHER-RÖSSLER

BRITISH JOURNAL OF PSYCHIATRY (2007), 191 (suppl. 51), s69–s75.

Borgwardt SJ et al. *Br J Psychiatry Suppl.* 2007;51:s69-75.

ARMS-T vs. ARMS-NT: GM reduction inferior frontal, superior temporal und insula



Regional Gray Matter Volume Abnormalities in the At Risk Mental State

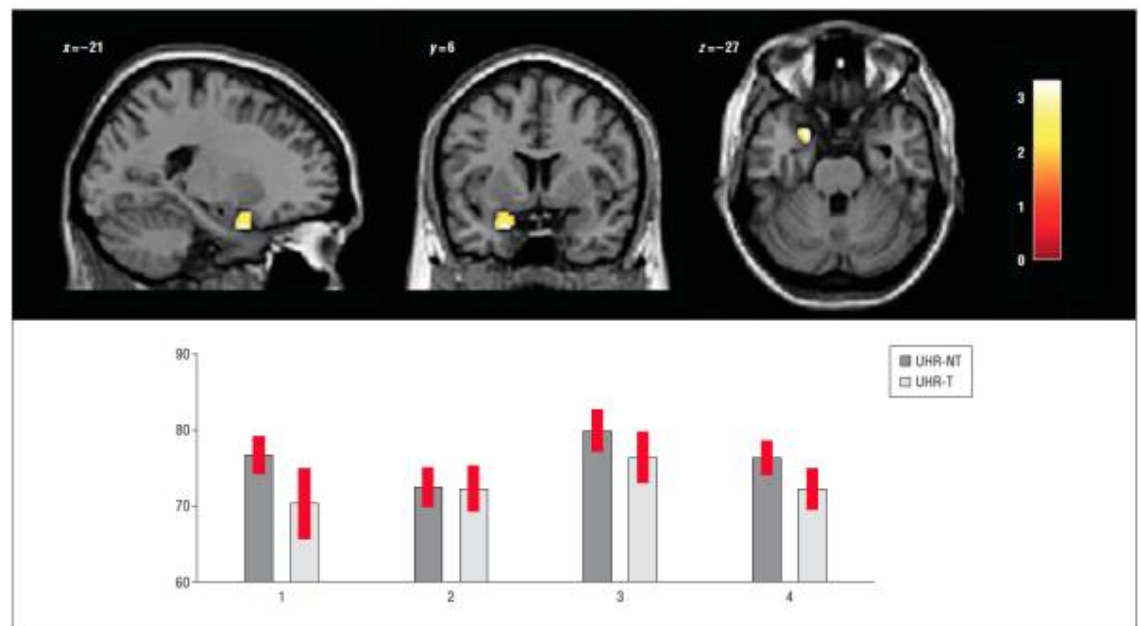
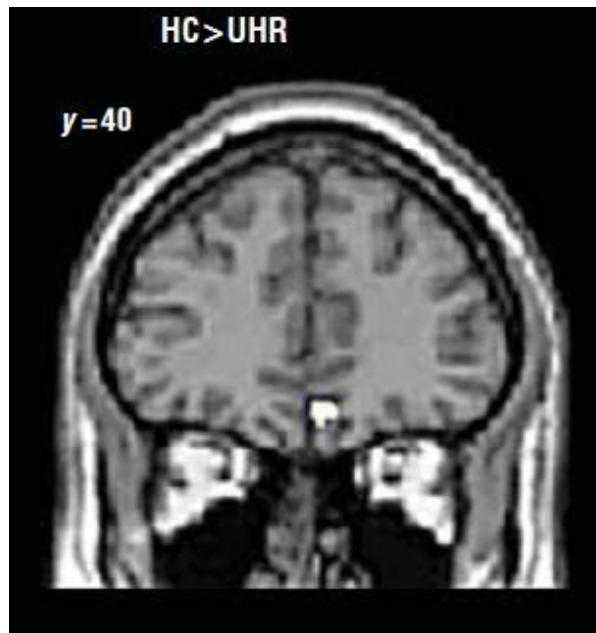
Stefan J. Borgwardt, Anita Riecher-Rössler, Paola Dazzan, Xavier Chitnis, Jacqueline Aston, Margret Drewe, Ute Gschwandtner, Sven Haller, Marlon Pflüger, Evelyne Rechsteiner, Marcus D'Souza, Rolf-Dieter Stieglitz, Ernst-Wilhelm Radü, and Philip K. McGuire

BIOL PSYCHIATRY 2007;61:1148–1156

Neuroanatomical Abnormalities That Predate the Onset of Psychosis

A Multicenter Study

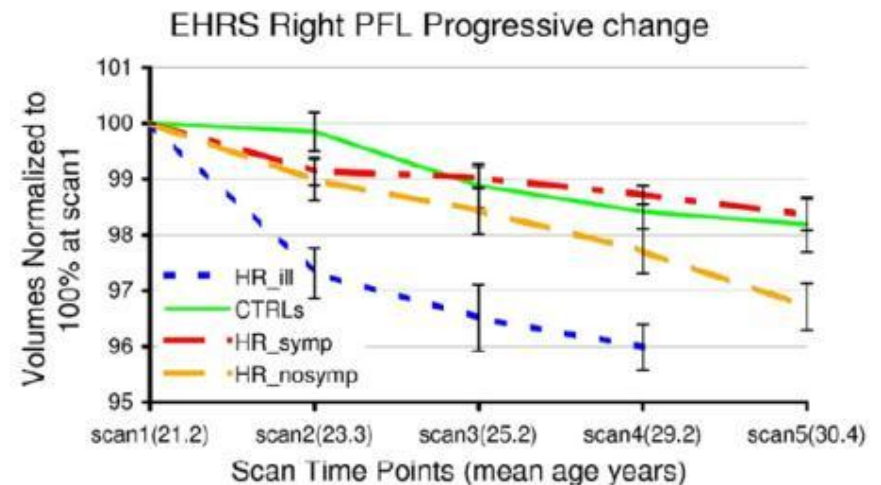
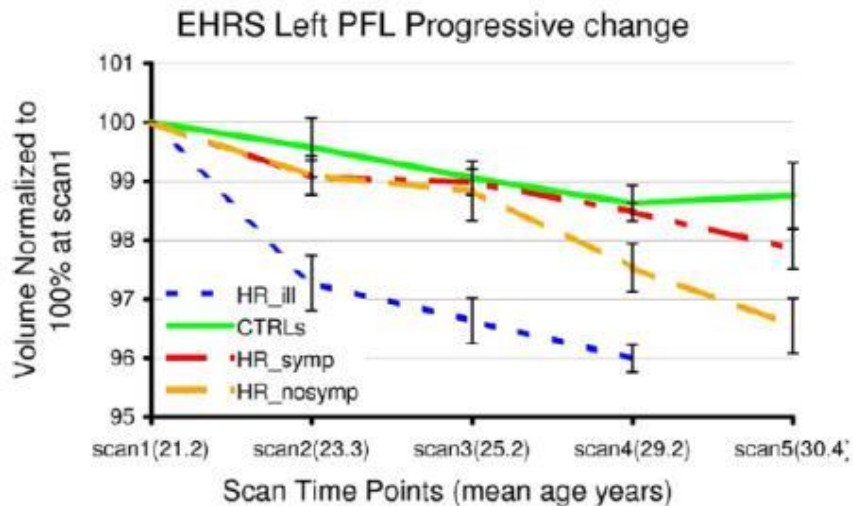
Andrea Mechelli, PhD; Anita Riecher-Rössler, MD; Eva M. Meisenzahl, MD; Stefania Tognin, BSc, MSc; Stephen J. Wood, PhD; Stefan J. Borgwardt, MD; Nikolaos Koutsouleris, MD; Alison R. Yung, MB, BS, PhD, FRANZCP; James M. Stone, BSc, MB, BS, MRCPsych, PhD; Lisa J. Phillips, MPsych, PhD; Patrick D. McGorry, MB, BS, MD, PhD, FRANZCP; Isabel Valli, MD; Dennis Velakoulis, MB, BS, FRANZCP; James Woolley, BSc, MBBS, MRCP, MRCPsych; Christos Pantelis, MB, BS, MD, MRCPsych, FRANZCP; Philip McGuire, BSc, MB, ChB, MD, PhD, FRCPsych



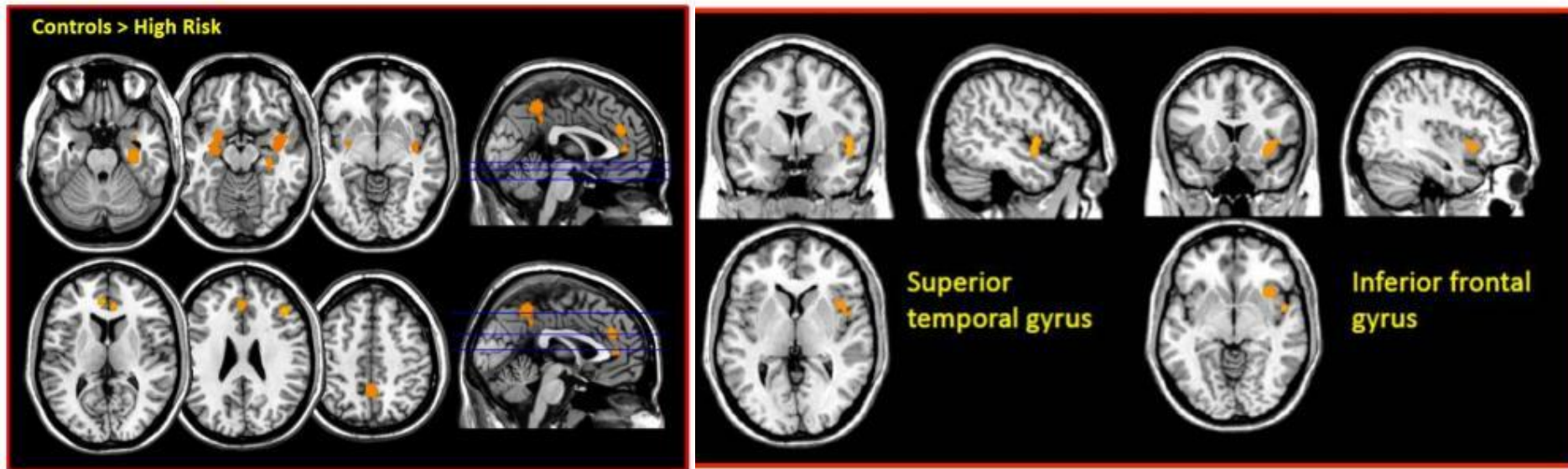
Longitudinal Volume Reductions in People at High Genetic Risk of Schizophrenia as They Develop Psychosis

Andrew M. McIntosh, David C. Owens, William J. Moorhead, Heather C. Whalley, Andrew C. Stanfield, Jeremy Hall, Eve C. Johnstone, and Stephen M. Lawrie

	HR[well] Male:Female	HR[symp] Male:Female	HR[ill] Male:Female	Control Subjects Male:Female	Age (SD)
Time 1	38:34	25:32	11:6	17:19	21.2 (2.8)
Time 2	17:14	12:14	5:3	12:7	23.2 (2.5)
Time 3	7:6	3:6	1:3	4:0	25.0 (2.5)
Time 4	15:17	15:16	4:2	13:5	29.2 (3.6)
Time 5	10:8	11:10	—	9:5	30.2 (3.0)



Voxel-based meta-analysis of vulnerability to psychosis (Control: n=746, HR: n=920)



GM reductions in HR: STG, ACC, Hippocampus/PHG

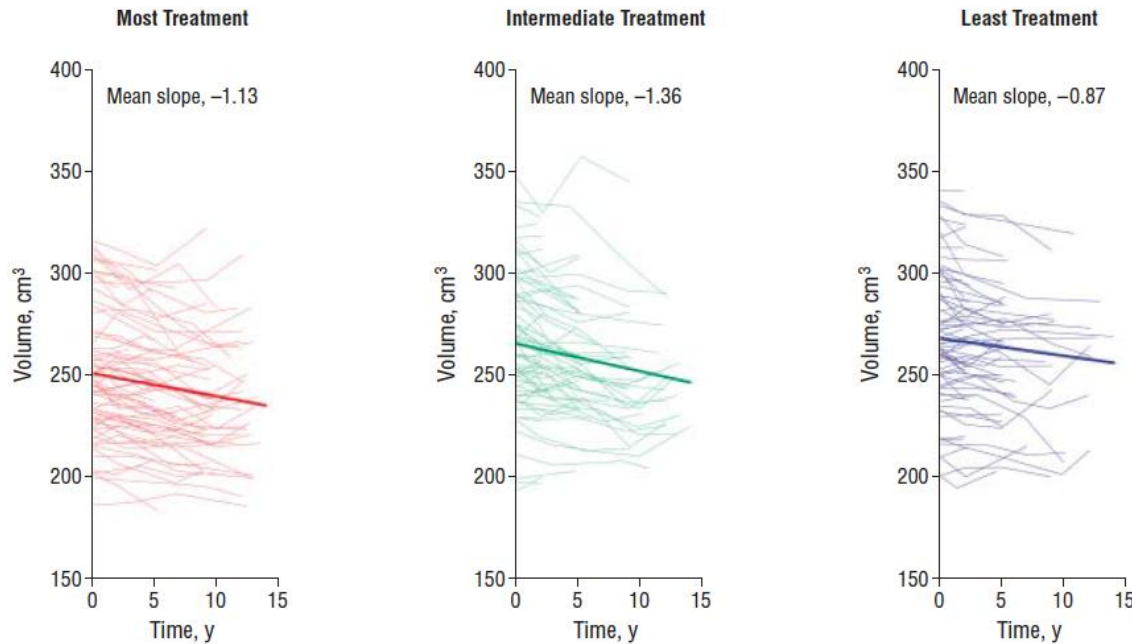
Converters: reduced STG and IFG

ACC: Anterior cingulate cortex; GM: Gray matter; PHG: parahippocampal gyrus; STG: Superior temporal gyrus.

Fusar-Poli P et al. *Neurosci Biobehav Rev* 2011 ;35(5):1175–85.

Antipsychotic drugs could shrink patients' brains

7 February 2011 | Nature | doi:10.1038/news.2011.75



More antipsychotic was associated with smaller GM. Illness severity had relatively modest correlations with tissue volume reduction, and alcohol/illicit drug misuse had no significant associations when effects of the other variables were adjusted.

Current Pharmaceutical Design, 2009, 15, 2535-2549

2535

The Effects of Antipsychotics on the Brain: What Have We Learnt from Structural Imaging of Schizophrenia? – A Systematic Review

R. Smieskova^{1,2}, P. Fusar-Poli⁴, P. Allen³, K. Bendfeldt², R.D. Stieglitz¹, J. Drewe³, E.W. Radue², P.K. McGuire³, A. Riecher-Rössler¹ and S.J. Borgwardt^{1,2,4,*}

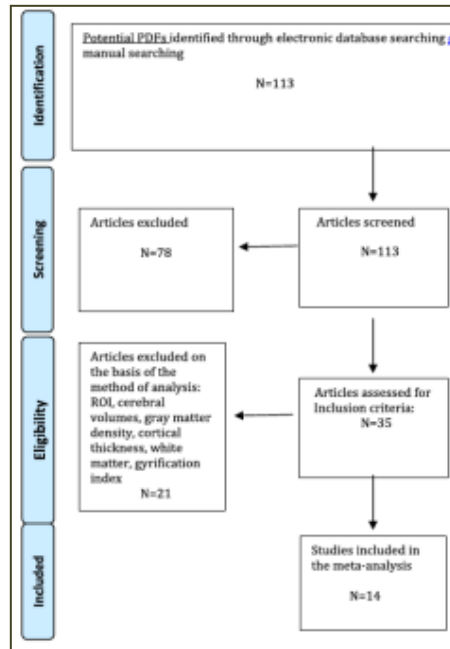
Long-term Antipsychotic Treatment and Brain Volumes

A Longitudinal Study of First-Episode Schizophrenia

Beng-Choon Ho, MRCPsych; Nancy C. Andreasen, MD, PhD; Steven Ziebell, BS; Ronald Pierson, MS; Vincent Magnotta, PhD

Arch Gen Psychiatry. 2011;68(2):128-137

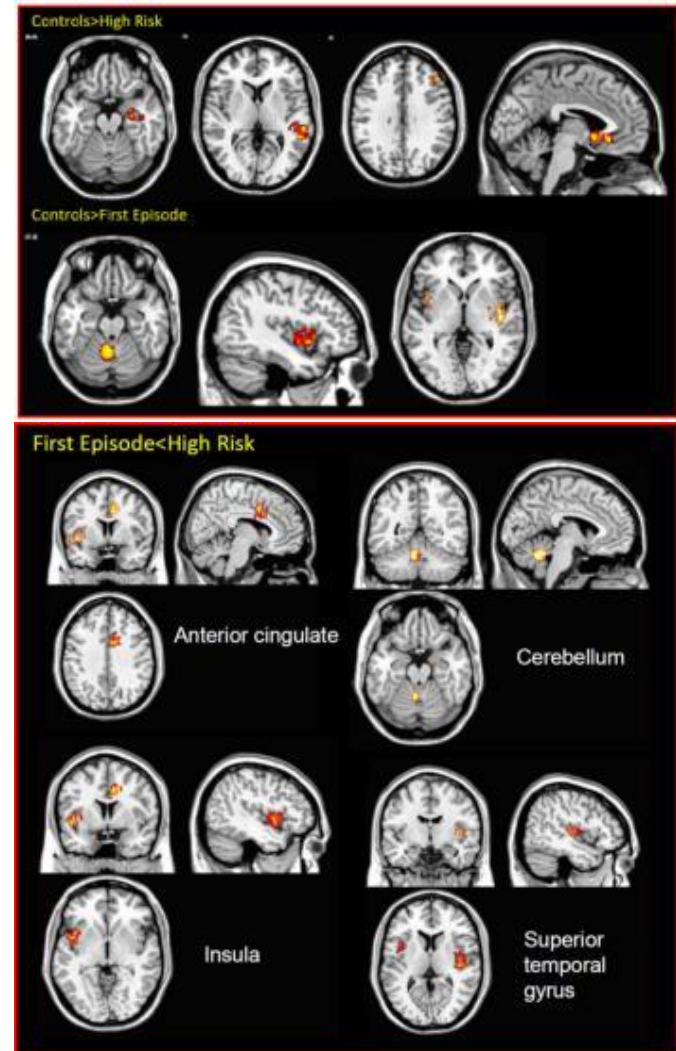
Voxel-based meta-analysis of vulnerability and onset related gray matter abnormalities in psychosis



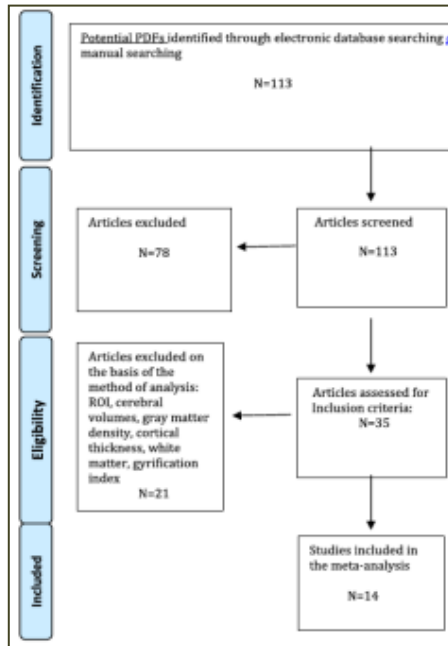
n= 198 antipsychotic-naive
high risk (HR)

n= 206 antipsychotic-naive
first-episode psychosis (FEP)

n=254 controls



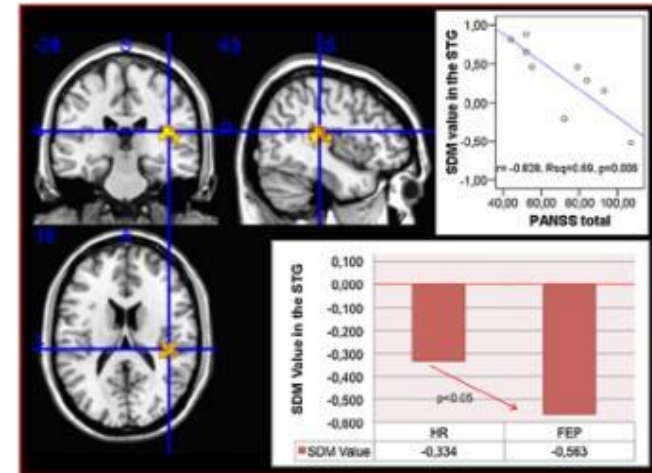
Voxel-based meta-analysis of vulnerability and onset related gray matter abnormalities in psychosis



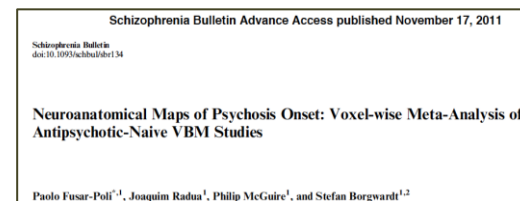
n= 198 antipsychotic-naive high risk (HR)

n= 206 antipsychotic-naive first-episode psychosis (FEP)

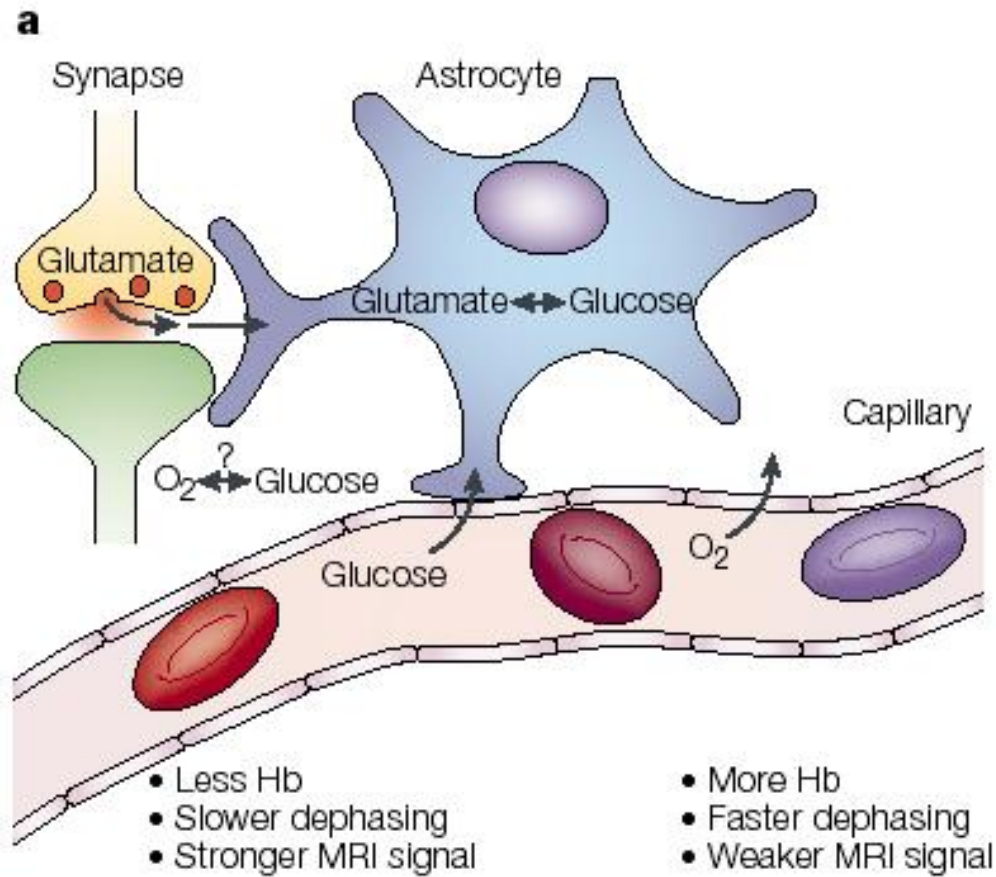
n=254 controls



- GM reductions in the temporal, limbic prefrontal cortex within the HR group and in the temporal insular cortex and cerebellum within the FEP group.
- Psychosis onset: GM decreases in temporal, anterior cingulate, cerebellar, and insular regions.
- GM alterations in the temporal regions directly related to severity of psychotic symptoms.

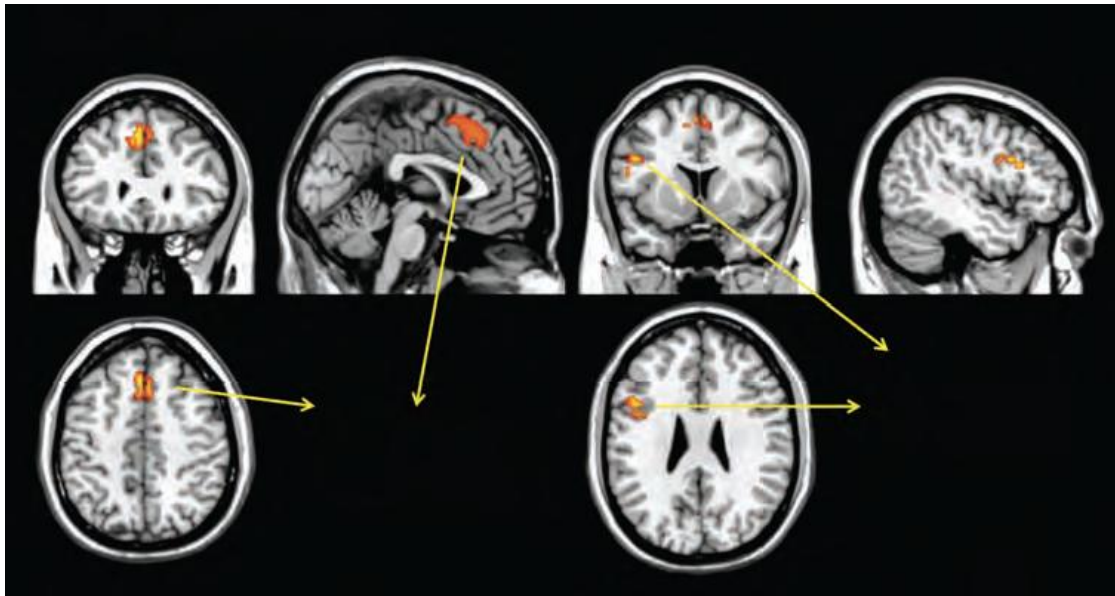

BOLD effect



Voxel-wise meta-analysis of fMRI studies in patients at clinical high risk for psychosis

Paolo Fusar-Poli, MD, PhD

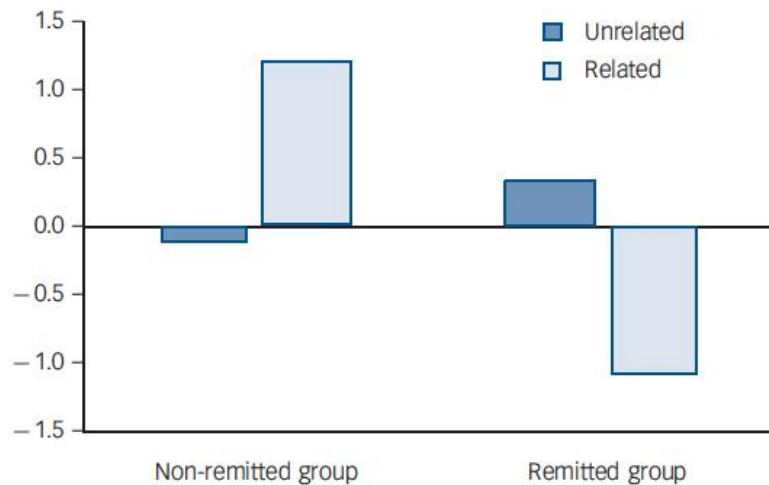
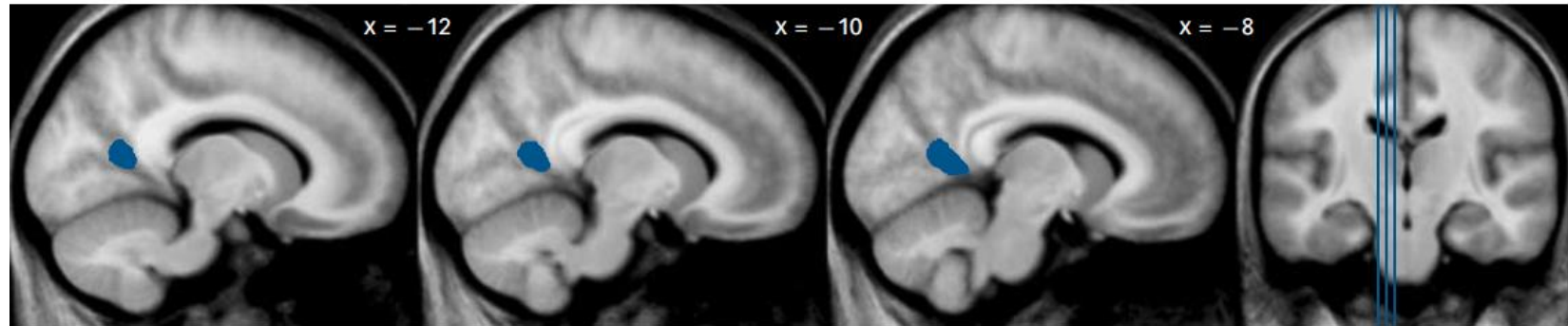


HR: reduced activation in the left inferior frontal gyrus, bilateral medial and superior frontal gyrus and the left anterior cingulate

J Psychiatry Neurosci 2012;37(2)

Functional magnetic resonance imaging correlates of memory encoding in relation to achieving remission in first-episode schizophrenia†


Michael Bodnar, Amelie M. Achim, Ashok K. Malla, Ridha Joober, Audrey Benoit and Martin Lepage



The British Journal of Psychiatry (2012)
200, 300–307. doi: 10.1192/bjp.bp.111.098046

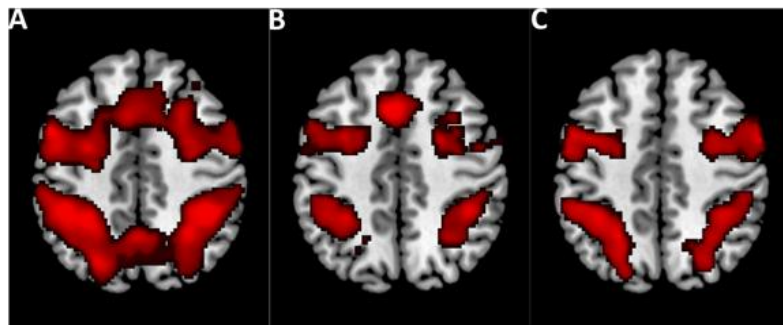
Fig. 1 Result of 'remitted > non-remitted' group comparison for semantic relatedness contrast ('unrelated pairs > related pairs').

Brain connectivity abnormalities predating the onset of psychosis



Middle frontal gyrus -> superior parietal lobule connectivity across HC, ARMS and FEP who received antipsychotics (medicated) or not (non-medicated)

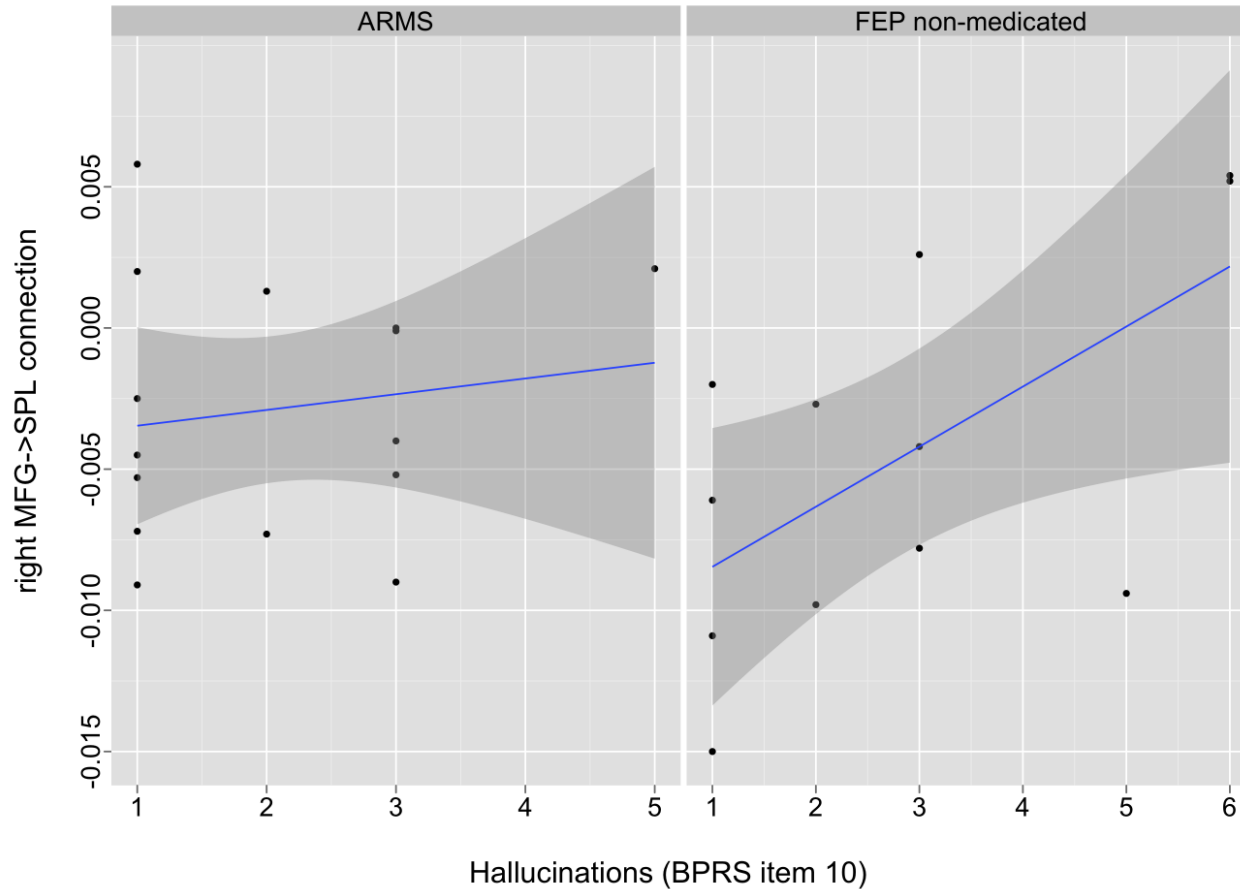
Abnormalities in Working Memory-induced modulation of connectivity may separate healthy controls from people with an at-risk mental state and patients with first-episode psychosis



Regional brain activation during working memory (2-back > 0-back). A, Healthy controls. B, Subjects with an at-risk mental state (ARMS). C, Patients experiencing a first-episode psychosis (FEP)

Schmidt, A, Smieskova R, Aston, J, Simon A, Allen P, Fusar-Poli P, McGuire PK, Riecher-Rössler A, Stephan KE, Borgwardt SJ (2013) Brain connectivity abnormalities predating the onset of psychosis: correlation with the effect of medication. Archives of General Psychiatry/JAMA Psychiatry, in press.

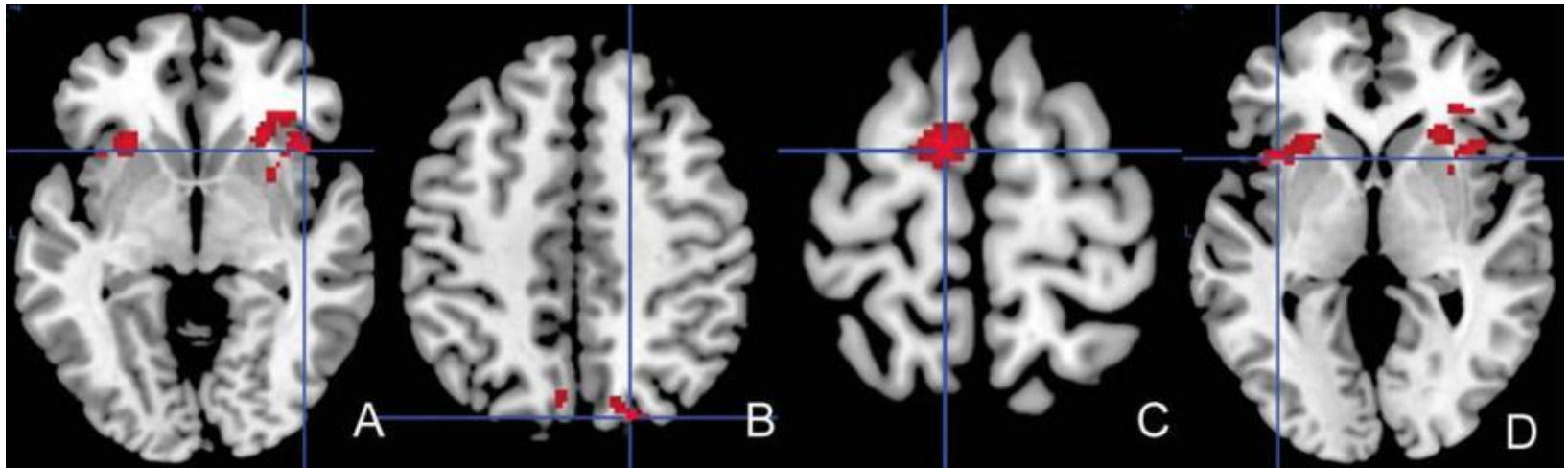
Brain connectivity abnormalities: effect of antipsychotics



- Abnormalities in WM-induced modulation of connectivity may separate healthy controls from people with an at-risk mental state and patients with first-episode psychosis
- Quantitative connectivity may infer the effects of antipsychotics and benefit the prediction of psychosis

Schmidt, A, Smieskova R, Aston, J, Simon A, Allen P, Fusar-Poli P, McGuire PK, Riecher-Rössler A, Stephan KE, Borgwardt SJ (2013) Brain connectivity abnormalities predating the onset of psychosis: correlation with the effect of medication. Archives of General Psychiatry/JAMA Psychiatry, 2013, in press.

Integration of structural and functional brain abnormalities




- Vulnerability to psychosis was associated with structural and neurofunctional alterations in fronto-temporo-parietal networks
- Neurofunctional differences were related to a higher risk for transition to psychosis, and thus may be related to different transition probabilities

Psychological Medicine (2011), 00, 1–13. © Cambridge University Press 2011
doi:10.1017/S0033291711002716

ORIGINAL ARTICLE

Insular volume abnormalities associated with different transition probabilities to psychosis

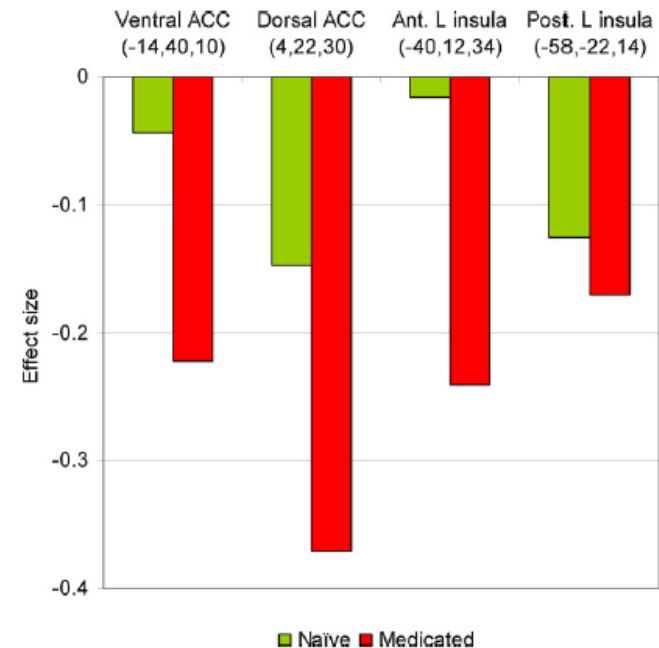
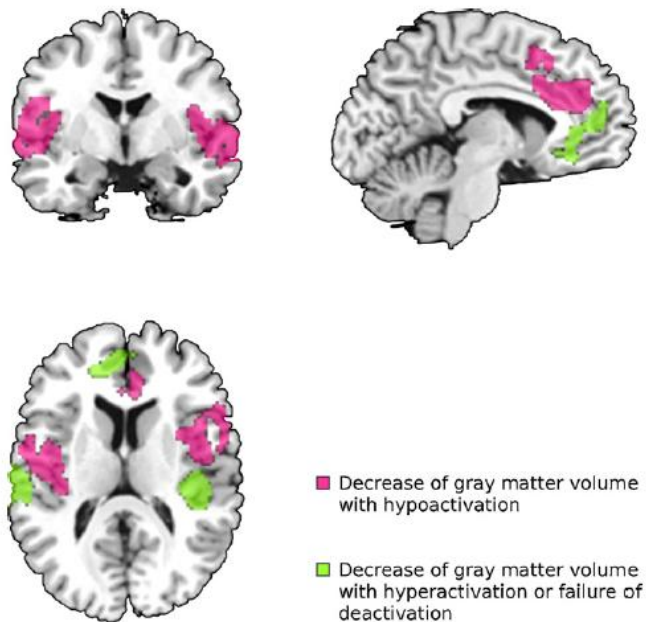
R. Smieskova^{1,2}, P. Fusar-Poli³, J. Aston¹, A. Simon^{4,5}, K. Bendfeldt⁵, C. Lenz⁶, R.-D. Stieglitz¹, P. McGuire³, A. Riecher-Rössler¹ and S. J. Borgwardt^{1,2,3*}



Meta-analysis

Multimodal meta-analysis of structural and functional brain changes in first episode psychosis and the effects of antipsychotic medication

J. Radua^{a,b}, S. Borgwardt^c, A. Crescini^d, D. Mataix-Cols^a, A. Meyer-Lindenberg^e,
P.K. McGuire^a, P. Fusar-Poli^{a,*}



Third generation and translational imaging

- › Moves away from simple investigations of the neurobiology underlying the early phases of schizophrenia
- › Translate imaging findings in the clinical field targeting longitudinal outcomes including transition, remission and response to preventative interventions
- › More complex techniques including diagnostic methods (e.g. support vector machines)

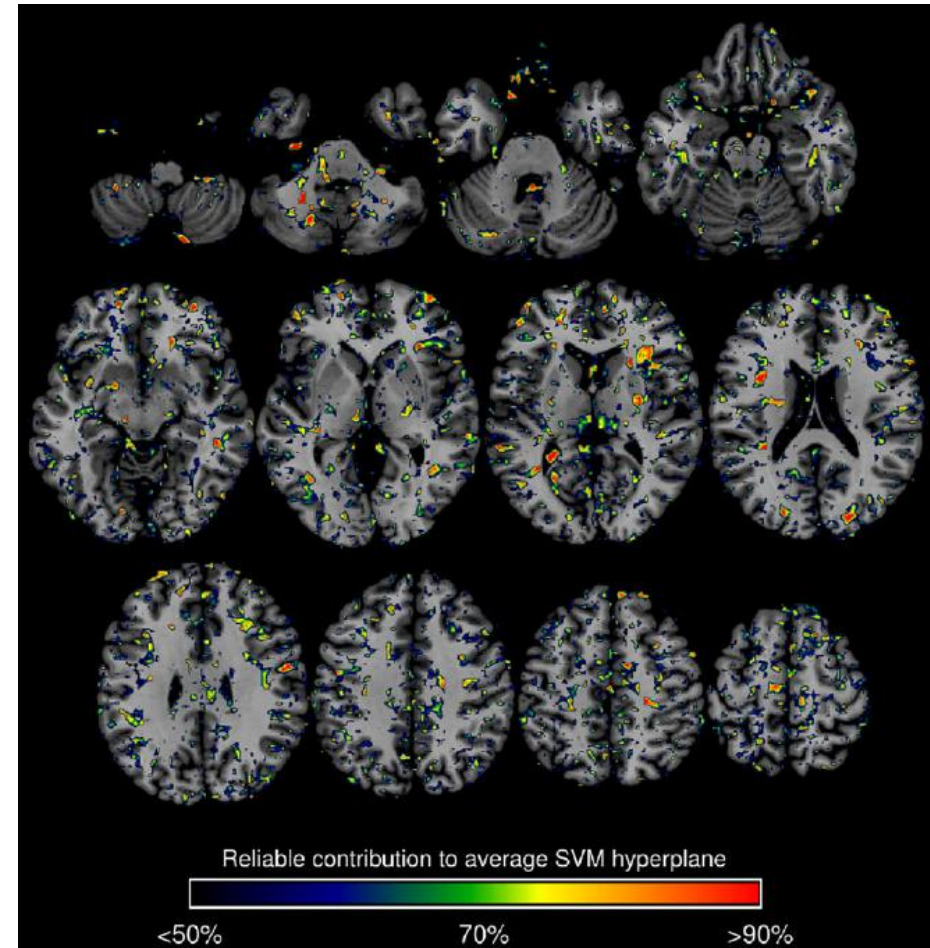
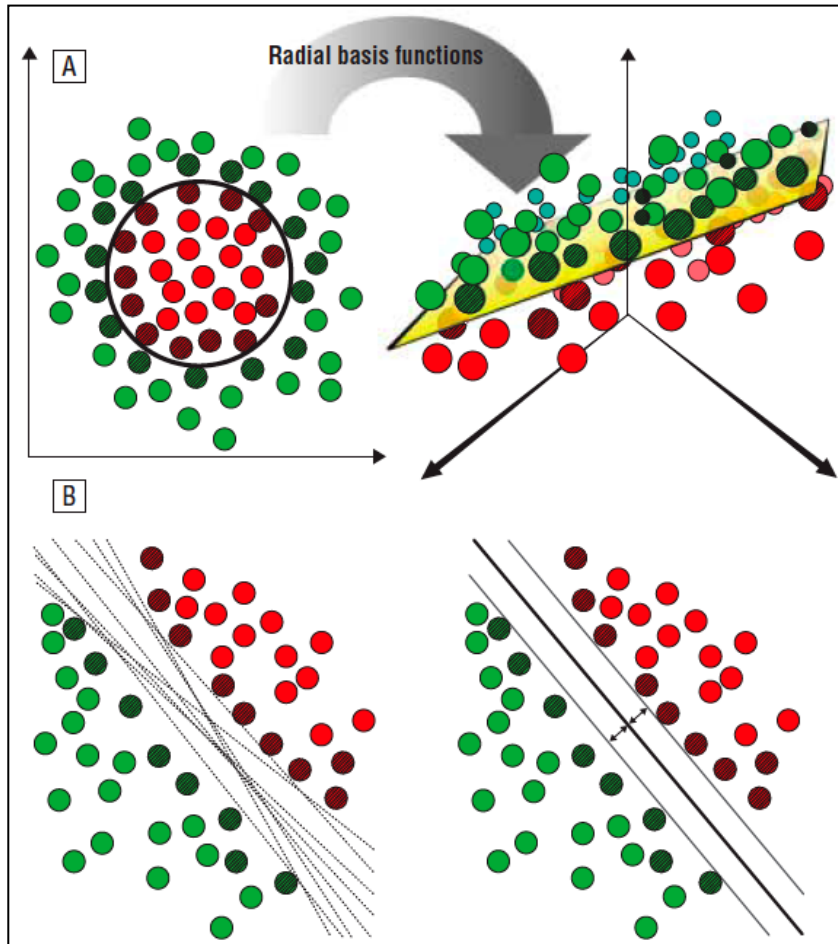
Third-generation neuroimaging in early schizophrenia: translating research evidence into clinical utility[†]

Stefan Borgwardt and Paolo Fusar-Poli

BJPsych

The British Journal of Psychiatry (2012)
200, 270–272. doi: 10.1192/bjp.bp.111.103234

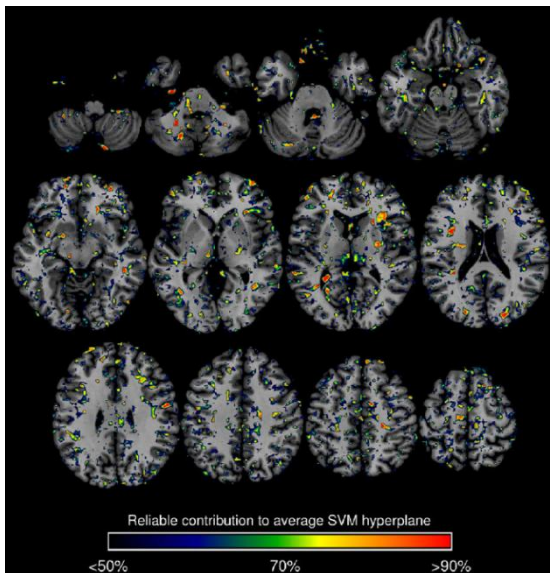
Pattern recognition tools for individualized neuroimaging



Individual prediction of early psychosis

Binary Classifiers	TP	TN	FP	FN	Sens (%)	Spec (%)	BAC (%)	FPR (%)	PPV (%)	NPV (%)
HC vs ARMS-T	20	15	1	2	93.8	90.9	92.3	6.3	95.2	88.2
HC vs ARMS-NT	30	9	12	2	42.9	90.9	66.9	57.1	62.5	81.8
ARMS-T vs ARMS-NT	14	17	4	2	81.0	87.5	84.2	19.1	77.8	89.5

Binary Classifiers	TP	TN	FP	FN	Sens (%)	Spec (%)	BAC (%)	FPR (%)	PPV (%)	NPV (%)
HC vs ARMS-T	19	12	4	3	75	86.4	80.7	25	82.7	80
HC vs FE	19	20	3	3	87	86.4	86.7	13	86.4	87
ARMS-T vs FE	11	21	2	5	91.3	68.8	80	8.7	84.6	80.8



Schizophrenia Bulletin Advance Access published November 10, 2011

Schizophrenia Bulletin
doi:10.1093/schbul/sbr145

Disease Prediction in the At-Risk Mental State for Psychosis Using Neuroanatomical Biomarkers: Results From the *FePsy* Study

Nikolaos Koutsouleris^{1,2}, Stefan Borgwardt², Eva M. Meisenzahl¹, Ronald Bottlender¹, Hans-Jürgen Möller¹, and Anita Riecher-Rössler²

Schizophrenia Bulletin Advance Access published September 11, 2012

Schizophrenia Bulletin
doi:10.1093/schbul/sbs095

Distinguishing Prodromal From First-Episode Psychosis Using Neuroanatomical Single-Subject Pattern Recognition


Stefan Borgwardt^{1,2}, Nikolaos Koutsouleris³, Jacqueline Aston¹, Erich Studerus¹, Renata Smieskova^{1,2}, Anita Riecher-Rössler¹, and Eva M. Meisenzahl¹

Summary

- › Bilateral prefrontal, limbic and temporo-parietal cortex reductions are neuroanatomical correlates of an increased vulnerability to psychosis.
- › High risk subjects who later become psychotic show additional volumetric reductions in superior temporal and inferior frontal areas relative to those who do not.
- › Changes in these areas may be crucial to the development of psychotic illness.
- › Functional and structural abnormalities in the high risk group may share a common pathophysiology
- › Prediction on outcomes at single-subject level might be a promising tool to translate imaging findings as clinical tool

The work presented here has been done by...

**Department of Psychiatry,
Basel, Switzerland**



**Institute of Psychiatry
King's College London, UK**



Many thanks to the patients and volunteers and ...



Section of Neuropsychiatry and Brain Imaging

Renata Smieskova, Anna Walter, Fabienne Harrisberger,
Niklaus Denier, Michel Röthlisberger, Johannes Wrege,

Early Detection Centre (FEPSY)

Anita Riecher-Rössler, Jacqueline Aston, Charlotte Rapp,
Erich Studerus, Hilal Bugra

Medical Image Analysis Centre (MIAC)

Ernst-Wilhelm Radue, Kerstin Bendfeldt, Stefan Traud,
Pascal Kuster

Department of Psychiatry

Marc Walter, Gerhard Wiesbeck, Rolf-Dieter Stieglitz,
Klaus Schmeck

Department of Neurology

Ludwig Kappos, Till Sprenger, Yvonne Naegelin

Department of Neuroradiology/Radiological Physics

Klaus Scheffler, Christoph Stippich, Claudia Lenz,
Markus Klarhoefer

Institute of Psychiatry, King's College London

Philip McGuire, Robin Murray,
Paolo Fusar-Poli, Oliver Howes,
Andrea Mechelli, Chris Chaddock,
Marco Picchioni, Sagnik Bhattacharyya,
Paul Allen, Lucia Valmaggia,
Richard Kanaan, Isabel Valli,
Matthew Kempton, OASIS-Team

Department of Neuroradiology, University of Geneva

Sven Haller

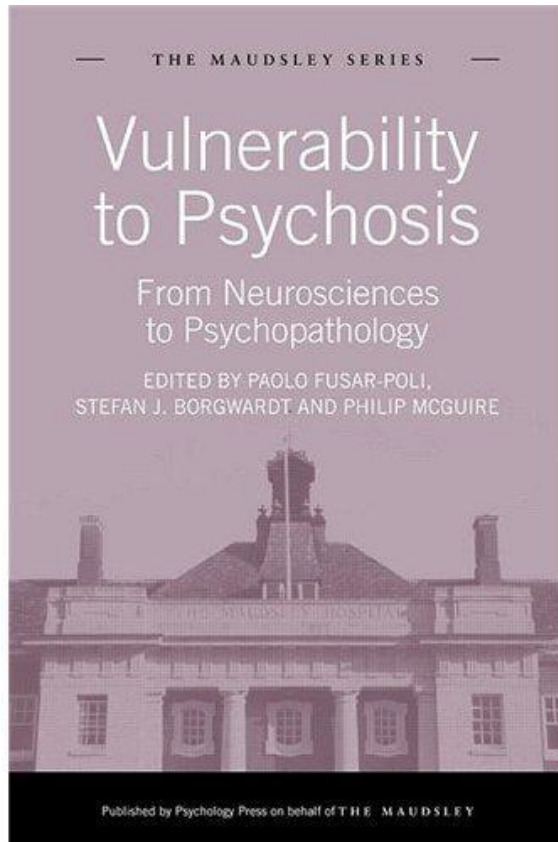
Department of Psychiatry, University of Munich

Nikos Koutsouleris, Eva Meisenzahl

Department of Psychiatry, University of Bonn

Ulrich Ettinger

If you don't know what to do next ...



Perspectives researchers and clinicians on the interaction of environmental with genetic and neurodevelopmental factors before the onset of psychosis

www.neuropsychiatry.ch

www.researchgate.net/profile/Stefan_Borgwardt/

E-mail: stefan.borgwardt@usb.ch